



## RetCam image analysis of optic disc morphology in premature infants and its relation to ischaemic brain injury

E McLoone, M O'Keefe, V Donoghue, S McLoone, N Horgan and B Lanigan

*Br. J. Ophthalmol.* 2006;90:465-471  
doi:10.1136/bjo.2005.078519

---

Updated information and services can be found at:  
<http://bjo.bmjournals.com/cgi/content/full/90/4/465>

---

*These include:*

### References

This article cites 33 articles, 12 of which can be accessed free at:  
<http://bjo.bmjournals.com/cgi/content/full/90/4/465#BIBL>

### Rapid responses

You can respond to this article at:  
<http://bjo.bmjournals.com/cgi/eletter-submit/90/4/465>

### Email alerting service

Receive free email alerts when new articles cite this article - sign up in the box at the top right corner of the article

---

### Topic collections

Articles on similar topics can be found in the following collections

[Infants](#) (570 articles)  
[Vision Research](#) (611 articles)  
[Other ophthalmology](#) (2150 articles)

---

### Notes

---

To order reprints of this article go to:  
<http://www.bmjournals.com/cgi/reprintform>

To subscribe to *British Journal of Ophthalmology* go to:  
<http://www.bmjournals.com/subscriptions/>

## EXTENDED REPORT

## RetCam image analysis of optic disc morphology in premature infants and its relation to ischaemic brain injury

E McLoone, M O'Keefe, V Donoghue, S McLoone, N Horgan, B Lanigan

*Br J Ophthalmol* 2006;90:465–471. doi: 10.1136/bjo.2005.078519

**Aims:** To assess optic disc characteristics in premature infants with and without ischaemic brain injury and to evaluate the role of optic disc morphology in dating the injury.

**Methods:** RetCam fundal images, cranial ultrasounds and magnetic resonance imaging (MRI) of 109 premature infants were analysed. The study cohort was divided into subgroups depending on the presence or absence of periventricular leucomalacia (PVL) and intraventricular haemorrhage (IVH). The control group consisted of infants with normal neuroimaging at term and 2 years of age. Using the image analysis software of the RetCam, optic disc diameter (ODD), optic disc area (ODA), and optic cup area (OCA) were measured at 33–34 weeks gestational age. As serial cranial ultrasonography had been performed, it was possible to date the brain injury in those infants with periventricular white matter (PVWM) damage.

**Results:** Although there was a trend towards reducing ODD, ODA, and OCA with increasing severity of IVH, only the IVH 4 group differed significantly from the controls for these parameters ( $p=0.002$ ,  $p=0.02$ , and  $p=0.04$ , respectively). 44.4% of infants with grade 4 IVH had small discs. Only one patient had a large cup in a normal sized disc; this patient had IVH 4. In patients with PVWM damage, the median time of insult was 27 weeks in those with small discs and 28 weeks in those with normal discs. This difference was not significant ( $p=0.23$ ).

**Conclusions:** Premature infants with IVH 4 have an increased incidence of optic nerve hypoplasia. We found no association between disc morphology and timing of brain injury.

See end of article for authors' affiliations

Correspondence to: Professor M O'Keefe, The Children's Hospital, Temple Street, Dublin 1, Republic of Ireland; [mokeefe@materprivate.ie](mailto:mokeefe@materprivate.ie)

Accepted for publication 10 November 2005

Ischaemic brain injury resulting in periventricular white matter (PVWM) damage is a major cause of visual impairment in premature infants where it is a more common cause of visual morbidity than retinopathy of prematurity. PVWM damage may arise as a result of periventricular leucomalacia (PVL) or periventricular haemorrhage. PVL is caused by an ischaemic process in the watershed zone that exists in the PVWM in the immature brain.<sup>1</sup> Intraventricular haemorrhage (IVH) occurs in 30–40% of all infants of less than 32 weeks gestational age.<sup>2</sup> It arises because of ischaemia of the subependymal germinal matrix tissue of the developing brain with subsequent bleeding from the fragile vasculature into the ventricles.<sup>3</sup> Periventricular haemorrhage (PVH) refers to the most severe form of IVH (grade 4 IVH) where there is associated parenchymal damage. As survival rates for premature infants in modern neonatal intensive care units continue to increase, the prevalence of ischaemic neonatal brain injury will also increase.

Several authors have reported the association between IVH and optic nerve hypoplasia (ONH).<sup>4–7</sup> However, the diagnosis of ONH in these studies was based on subjective analysis of the optic disc. Bilateral, mild ONH can prove difficult to diagnose from clinical appearance alone. Furthermore, hypoplasia may occur in optic discs of normal size with large optic cups because of a reduced number of axons.<sup>8,9</sup> Pallor may be an additional feature of ONH. The simultaneous occurrence of ONH and optic atrophy is being recognised with increasing frequency, further adding to the confusion over the definition of ONH.<sup>8,10</sup>

Hellstrom *et al* analysed fundal photographs of premature children and reported a possible role for optic disc morphology in dating ischaemic brain insults.<sup>11–13</sup>

This study attempts to assess the optic disc in a cohort of premature babies to further elucidate the association between ONH and ischaemic neonatal brain injury and to

evaluate the role of optic disc morphology in determining the timing of brain injury.

## METHODS

We identified all babies screened for ROP (screening criteria of <31 weeks gestational age and/or  $\leq 1500$  g birth weight) since the introduction of the RetCam 120 (Massie Laboratories, Dublin, CA, USA) in the neonatal unit of the National Maternity Hospital, Dublin, in November 1999. These were then cross referenced with a record book of premature babies screened for IVH (screening criteria of <34 weeks gestational age and/or  $\leq 1500$  g birth weight) in the same unit. Portable cranial ultrasonography was routinely performed in the neonatal unit within the first 48 hours of life and subsequently on days 3, 7, 14, and pre-discharge. Additional scans were performed as indicated by the neurological status of the neonate. Images were obtained through the anterior fontanelle in both right and left sagittal and coronal planes.

## RetCam image analysis

All images were taken with the wide angle 130° head for the RetCam and were analysed by a single observer (EML) who was masked to the results of the cranial ultrasonography. The best images for each eye, at a corrected age of 33–34 weeks, were selected for each baby. Eyes with unfocused or poorly centred disc images were excluded. Using the image analysis software of the RetCam 120, the optic disc area (ODA) and optic cup area (OCA) were measured by carefully delineating

**Abbreviations:** CUSS, cranial ultrasound scan; IVH, intraventricular haemorrhage; MRI, magnetic resonance imaging; OCA, optic cup area; ODA, optic disc area; ODD, optic disc diameter; ONH, optic nerve hypoplasia; ORA, optic disc rim area; PVL, periventricular leucomalacia; PVWM, periventricular white matter; ROP, retinopathy of prematurity

their outlines with a cursor. The areas were then calculated by the computer. Some of the eyes had no physiological cupping. In these cases, the OCA was assigned a value of 0. The optic disc diameter (ODD) was assessed by marking the limits of the horizontal diameter with the cursor. The RetCam software automatically incorporates a conversion factor of 0.03 mm/pixel to yield real distance values. Optic disc rim area (ORA) was recorded as the difference between ODA and OCA.

### Cerebral image analysis

The cranial ultrasound scan (CUSS) examinations were performed and interpreted by a single consultant paediatric radiologist (VD) who was unaware of the optic disc morphology. IVH was graded according to the method of Papile *et al*: grade 1 is haemorrhage confined to the subependymal germinal matrix, grade 2 is an intraventricular bleed, grade 3 is IVH with ventricular dilation, and grade 4 is IVH associated with parenchymal haemorrhage.<sup>14</sup> Grade 4 IVH is also known as periventricular haemorrhage (PVH).

Since November 2001, magnetic resonance imaging (MRI) has been performed on all premature babies at term, and subsequently at 2 years of age, as PVL may not be evident on initial neuroimaging.<sup>15</sup> Therefore, for the purposes of this study, we defined our control population as premature babies with normal cranial ultrasonography and normal MRIs at term and at 2 years of age.

In cases where PVWM damage was noted on CUSS, the ultrasound images and any available MRIs were carefully reviewed in order to distinguish between PVH and PVL.<sup>16</sup> Intraventricular haemorrhage may be present in both of these conditions and is not helpful in their differentiation. While PVL typically occurs posteriorly, adjacent to the trigone of the lateral ventricles, and PVH typically occurs anteriorly, just dorsal and lateral to the external angle of the lateral ventricle, either lesion may be more extensive and involve the PVWM from frontal to parieto-occipital regions.<sup>3</sup> Other features which may help in distinguishing these conditions are outlined in table 1.<sup>17</sup>

### Timing of parenchymal injury

PVWM damage usually occurs between 24–34 weeks gestation.<sup>13</sup> As serial CUSS were performed on the premature babies in this study, it was possible to estimate the timing of the parenchymal damage in the PVH and PVL groups in most instances. In other words, if the initial CUSS was normal at 24 hours but parenchymal damage was evident at 72 hours, then the insult was estimated to have occurred within the first postnatal week. In two cases with PVL, the insult could not be timed as the parenchymal damage was only detected on the 2 year MRI scan and was not evident on the initial CUSS. Although prenatal cases of PVH and PVL are known to occur occasionally, the injury occurred postnatally in all of our study patients.

### Baseline characteristics

Gestational age and birth weight were recorded for each patient. Maternal notes were reviewed to exclude any cases with a history of maternal alcohol abuse or infection during pregnancy. The severity of retinopathy of prematurity (ROP), if present, was also noted by reviewing all available RetCam images.

### Statistical analysis

Analysis was performed using Matlab 6.5 (Statistics Toolbox 4.0). Where data were available for both eyes of an individual, the mean of the measurements of the two eyes was calculated for each optic disc parameter. In cases where only one eye had images of optimal quality, the disc parameters for this eye were included in the analysis. This approach was also adopted by Hellstrom *et al* in their analysis of optic discs.

As the data were not normally distributed, differences in baseline characteristics and optic disc parameters between the various subgroups were analysed using non-parametric methods such as Kruskal-Wallis ANOVA, Wilcoxon rank sum test, and Fisher's exact test as appropriate. A *p* value of less than 0.05 was considered significant.

The data on the disc parameters are displayed graphically using box plots (a five measure summary of the variables: median, upper and lower quartiles, minimum and maximum values).

## RESULTS

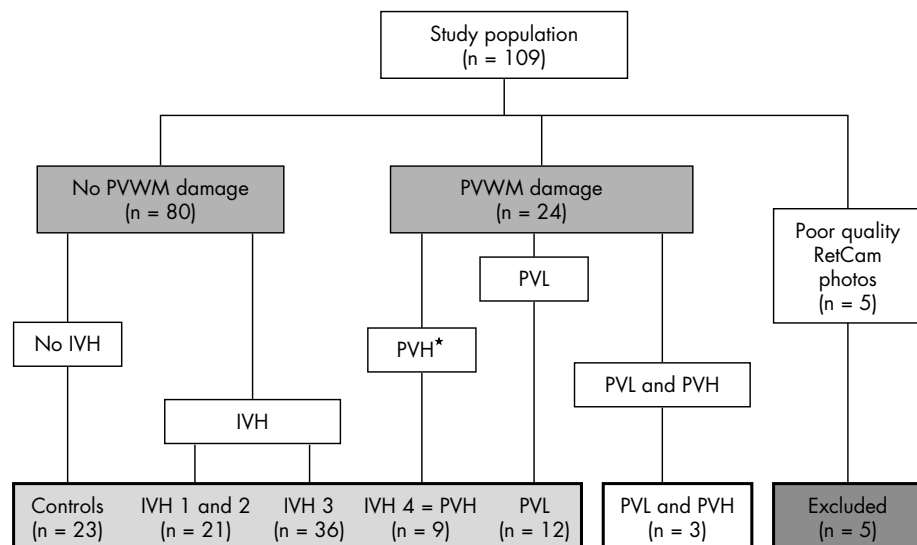
The study population comprised 109 infants with RetCam fundal images and CUSS images. Five patients were excluded because of unfocused or poorly centred fundal images; of these, two had normal neuroimaging, two had IVH 3, and one had PVL. Based on the neuroimaging findings, we categorised our remaining patients into two broad groups; those with and without PVWM damage (fig 1). From table 2 it is evident that babies with PVWM damage had significantly smaller optic discs than babies without PVWM damage (*p* = 0.03, Wilcoxon rank sum).

The data were further categorised into subgroups in order to elucidate the influence of IVH (grades 1–4) and PVL on optic disc morphology (fig 1). Patients with IVH 1 and IVH 2 were combined into one group as they did not differ significantly in their baseline characteristics and ocular outcomes and there were only four patients with IVH 2. Three infants who had evidence of both periventricular haemorrhage and periventricular leucomalacia on neuroimaging were excluded from further analysis. The baseline characteristics of these subgroups are summarised in table 3.

The gestational age for the study population as a whole ranged from 24 weeks to 33 weeks and the birth weight from 540 g to 2400 g. There was no statistically significant difference in median birth weight between the groups (*p* = 0.51, Kruskal-Wallis ANOVA) and the only statistically significant difference in terms of median gestational age was

**Table 1** Classification of periventricular white matter damage

Characteristic	Periventricular haemorrhage	Periventricular leucomalacia
Infarct type	Venous	Arterial
Periventricular location	Anterior	Posterior
Haemorrhagic lesion	Always	Rarely
Laterality	Unilateral > bilateral	Bilateral > unilateral
Symmetry	Asymmetric	Symmetric
Porencephalic cyst	Associated feature	Not associated
Ventriculomegaly	Regular dilation of the ventricles	Irregularity of the ventricular outline



**Figure 1** Breakdown of the study population. PVWM, periventricular white matter; IVH, intraventricular haemorrhage; PVH, periventricular haemorrhage; PVL, periventricular leucomalacia. \*Periventricular haemorrhage is equivalent to IVH grade 4.

**Table 2** Optic disc parameters in premature infants with and without periventricular white matter (PVWM) damage

Variable (median values)	No PVWM damage (n = 80)	PVWM damage (n = 24)	p Value
Gestational age (weeks)	28.0	27.0	0.20
Body weight (g)	1050.0	1008.0	0.68
Optic disc diameter (mm)	1.05	0.95	0.002
Optic disc area (mm <sup>2</sup> )	1.13	1.06	0.03
Optic cup area (mm <sup>2</sup> )	0.09	0.08	0.07
Optic rim area (mm <sup>2</sup> )	1.03	0.95	0.02

**Table 3** Baseline characteristics of the subgroups

Variable	No PVWM damage (n = 80)			PVWM damage (n = 21)	
	Controls (n = 23)	IVH 1 and 2 (n = 21)	IVH 3 (n = 36)	IVH 4 (n = 9)	PVL (n = 12)
Gestational age (weeks) (median)	28.0	28.0	27.5	27.0	27.5
Body weight (g) (median)	1100.0	980.0	1075.0	1060.0	1008.0
<b>Sex</b>	<b>No (%)</b>	<b>No (%)</b>	<b>No (%)</b>	<b>No (%)</b>	<b>No (%)</b>
Male	14 (61)	12 (57)	21 (58)	2 (22)	4 (33)
Female	9 (39)	9 (43)	15 (42)	7 (78)	8 (67)
<b>ROP</b>	<b>No (%)</b>	<b>No (%)</b>	<b>No (%)</b>	<b>No (%)</b>	<b>No (%)</b>
No ROP	19 (82)	13 (62)	28 (78)	6 (67)	5 (42)
Subthreshold ROP	2 (9)	3 (14)	3 (8)	2 (22)	3 (25)
Threshold ROP	2 (9)	5 (24)	5 (14)	1 (11)	4 (33)

IVH, intraventricular haemorrhage; PVL, periventricular leucomalacia; ROP, retinopathy of prematurity.

between the control and IVH 4 groups ( $p = 0.03$ , Wilcoxon rank sum). Neither was there a significant difference in sex distribution between the groups ( $p > 0.06$ , Fisher's exact test).

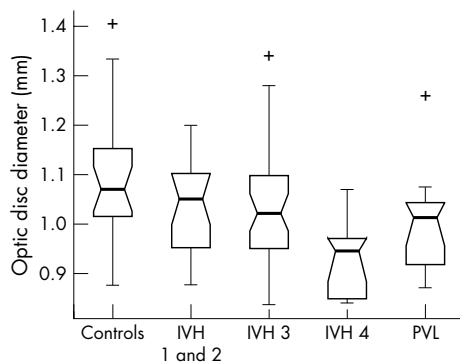
In all, 28.7% of the IVH patients compared to 17.4% of the controls had ROP; however, this was not statistically significant ( $p = 0.22$ , Fisher's exact test). Only the PVL group had significantly more patients with ROP than the control group ( $p = 0.02$ , Fisher's exact test).

**Disc parameters**

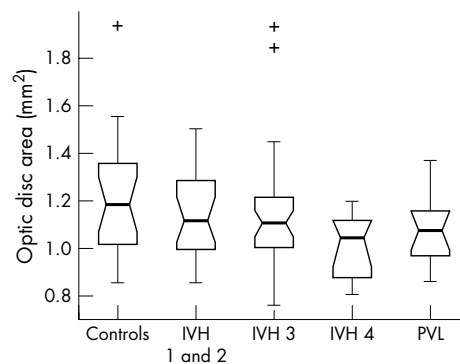
Kruskal-Wallis analysis of the data identified a significant variation in ODD ( $p = 0.01$ ) and OCA ( $p = 0.02$ ) between the study subgroups. No significant difference in ODA ( $p = 0.15$ ) or ORA ( $p = 0.20$ ) was detected.

The box plots in figures 2–5 summarise the disc parameter findings for the various subgroups. The IVH 4 group differed significantly from the controls for all four of the disc parameters assessed (Wilcoxon rank sum); median ODD (0.95 mm  $\nu$  1.07 mm respectively,  $p = 0.002$ ), median ODA (1.05 mm<sup>2</sup>  $\nu$  1.19 mm<sup>2</sup>,  $p = 0.02$ ), median OCA (0.06 mm<sup>2</sup>  $\nu$  0.12 mm<sup>2</sup>,  $p = 0.007$ ), and median ORA (0.93 mm<sup>2</sup>  $\nu$  1.09 mm<sup>2</sup>,  $p = 0.04$ ).

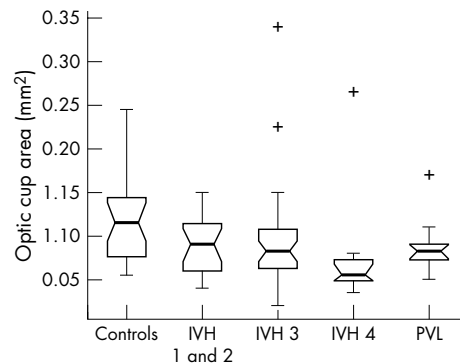
The PVL group differed significantly from the controls only in terms of median ODD (1.01 mm  $\nu$  1.07 mm respectively,  $p = 0.02$ ). There was no significant difference in median ODA (1.08 mm<sup>2</sup>  $\nu$  1.19 mm<sup>2</sup>,  $p = 0.08$ ), median OCA (0.08 mm<sup>2</sup>  $\nu$  0.12 mm<sup>2</sup>,  $p = 0.06$ ) or median ORA (0.98 mm<sup>2</sup>  $\nu$  1.09 mm<sup>2</sup>,  $p = 0.14$ ).



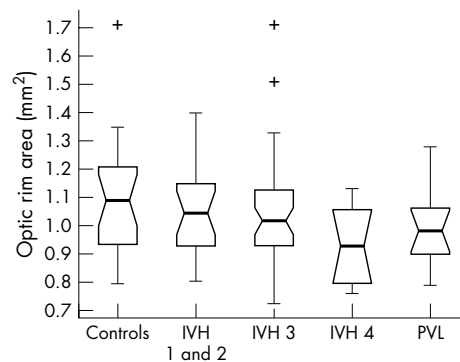
**Figure 2** Optic disc diameter in the study population (range 0.81–1.41 mm).



**Figure 3** Optic disc area in the study population (range 0.66–1.94 mm<sup>2</sup>).



**Figure 4** Optic cup area in the study population (range 0.02–0.34 mm<sup>2</sup>).



**Figure 5** Optic rim area in the study population (range 0.64–1.71 mm<sup>2</sup>).

Neither the IVH 1 and 2 nor the IVH 3 groups differed significantly from controls for any of the optic disc parameters measured ( $p > 0.06$ , Wilcoxon rank sum).

The box plot data suggest trends of decreasing ODD, ODA, OCA, and ORA with increasing IVH severity. The significance of these trends was assessed by way of a  $\chi^2$  test for linear trend analysis of the proportion of discs with values less than the median value for the control group. This analysis confirmed that the observed trends were significant for all four disc parameters: ODD ( $p = 0.002$ ), ODA ( $p = 0.028$ ), OCA ( $p = 0.005$ ) and ORA ( $p = 0.028$ ).

### 5th and 95th percentiles

Small and large optic discs were defined as those falling outside the 5th and 95th percentiles for ODD and ODA in the control group. Small and large optic cup areas and optic rim areas were similarly defined. From table 4, we can see that the IVH 4 group had significantly more hypoplastic discs than the control group (Fisher's exact test,  $p = 0.03$  for ODD, ODA, and ORA and  $p = 0.003$  for OCA).

Only one patient had a large optic cup in a normal sized disc (fig 6). The other patients with large optic cups had a correspondingly large optic disc size and therefore did not fit Jacobsons *et al* criteria for atypical ONH.<sup>8</sup>

### Timing of parenchymal injury

The estimated timing of the parenchymal damage in the PVH (IVH 4) and PVL groups is given in table 5. There was no significant difference in the median time of insult between the two groups (27 weeks *v* 28 weeks respectively,  $p = 0.14$ , Wilcoxon rank sum). The time of insult ranged from 25–30 weeks (median 27 weeks) for the five patients with periventricular white matter damage and small optic disc areas and ranged from 26–31 weeks (median 28 weeks) for the remaining patients with PVWM damage but normal optic disc areas (table 5). This was not statistically significant ( $p = 0.23$ , Wilcoxon rank sum). Evaluation of Spearman's rank correlation between timing of insult and the optic disc parameters did not yield any significant results (ODD:  $p = 0.60$ , ODA:  $p = 0.55$ , OCA:  $p = 0.29$ , ORA:  $p = 0.76$ ). Neither was severity of injury nor location of injury correlated with optic disc morphology in patients with PVWM damage.

### DISCUSSION

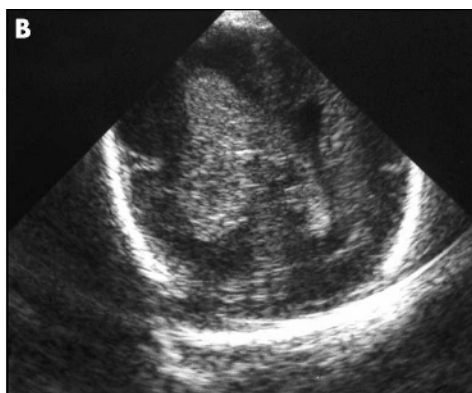
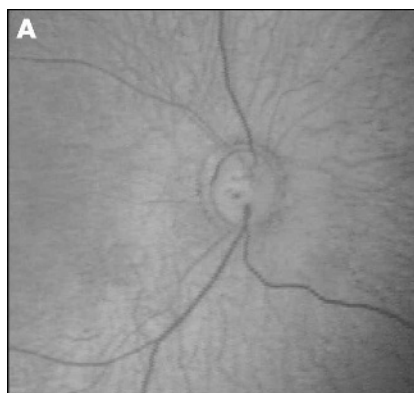
The incidence of IVH has been shown to increase progressively with decreasing gestational age<sup>18–19</sup>; 61% of our study population, with gestational age ranging from 24–33 weeks, had IVH. Only the IVH 4 group differed significantly from the controls in terms of median gestational age, suggesting that low gestational age also predisposes to a more severe grade of IVH.

Although there was a trend towards a higher incidence of ROP in the IVH patients, this was not found to be statistically significant. King and Cronin, Amato *et al*, and Phillips *et al* also found no statistical association between ROP and IVH.<sup>6, 20–21</sup> However, other authors have reported an association.<sup>22–24</sup> Of note, in these latter studies, CUSS alone was used to diagnose IVH; therefore cases of PVL may have been included in these cohorts. Interestingly, our PVL group did have significantly more patients with ROP than the control group ( $p = 0.02$ , Wilcoxon rank sum). Perhaps, the increased incidence of ROP in the PVL group reflects a more severe hypoxia in these patients, which also impacts on the immature retinal vasculature.

Within our study population, only those babies with grade 4 IVH had significantly more hypoplastic discs than the control group. As the optic radiations pass adjacent to the trigone of the lateral ventricles, PVWM damage can result in ganglion cell axonal loss by retrograde trans-synaptic

**Table 4** Number of patients with disc parameters outside the 5th and 95th percentiles of the control group

Variable	Controls (n = 23)	IVH 1 and 2 (n = 21)	IVH 3 (n = 36)	IVH 4 (n = 9)	PVL (n = 12)
	No (%)	No (%)	No (%)	No (%)	No (%)
Small ODD (<0.91 mm)	2 (8.7)	2 (9.5)	5 (13.9)	4 (44.4)	3 (25.0)
Large ODD (>1.32 mm)	2 (8.7)	0 (0.0)	1 (2.8)	0 (0.0)	0 (0.0)
Small ODA (<0.94 mm <sup>2</sup> )	2 (8.7)	3 (14.3)	5 (13.9)	4 (44.4)	1 (8.3)
Large ODA (>1.55 mm <sup>2</sup> )	2 (8.7)	0 (0.0)	2 (5.6)	0 (0.0)	0 (0.0)
Small OCA (<0.06 mm <sup>2</sup> )	1 (4.3)	4 (19.0)	6 (16.7)	5 (55.6)	1 (8.3)
Large OCA (>0.24 mm <sup>2</sup> )	2 (8.7)	0 (0.0)	1 (2.8)	1 (0.64)	0 (0.0)
Small ORA (<0.87 mm <sup>2</sup> )	2 (8.7)	4 (19.0)	5 (13.9)	4 (44.4)	3 (25.0)
Large ORA (>1.35 mm <sup>2</sup> )	2 (8.7)	1 (4.8)	2 (5.6)	0 (0.0)	0 (0.0)

**Figure 6** Fundal image (A) and cranial ultrasound (B) of the patient with a large optic cup in a normal sized disc in the presence of a right grade 4/left grade 3 IVH.**Table 5** Patients with periventricular white matter (PVWM) damage

Patient	GA	ODA (mm <sup>2</sup> )	PVWM damage			Associated IVH grade	Associated porencephaly	Time of insult	Diagnosis
			Severity	Localisation†	Symmetry				
1	29	1.19	Severe	(R) ant-mid	No	(R) G4, (L) G3	Yes	Day 3	PVH
2	26	1.09	Severe	(R) ant-mid	No	(R) G4, (L) G3	No	Day 2	PVH
3	25	<b>0.93</b>	Severe	(R) ant-mid-post, (L) ant-mid-post	No	(R) G4, (L) G4	Yes	Day 2	PVH
4	25	<b>0.90</b>	Severe	(R) ant-mid	No	(R) G4, (L) G3	Yes	Day 2	PVH
5*	28	1.07	Mod	(R) ant-mid	No	(R) G4, (L) G3	No	Day 3	PVH
6	27	<b>0.81</b>	Mod	(L) ant-mid	No	(R) G3, (L) G4	No	Day 2	PVH
7	28	1.20	Severe	(R) ant-mid-post, (L) ant-mid-post	No	(R) G4, (L) G4	No	Day 2	PVH
8	27	<b>0.83</b>	Severe	(L) ant-mid	No	(R) G3, (L) G4	No	Day 3	PVH
9	26	1.05	Severe	(R) ant-mid, (L) ant-mid-post	No	(R) G4, (L) G4	Yes	Day 3	PVH
10	27	1.07	Severe	(R) post, (L) mid-post	No	(R) G3, (L) G3	No	Day 2	PVL
11	29	1.09	Mod	(R) mid-post, (L) mid-post	Yes	(R) G1, (L) G1	No	Day 7	PVL
12	25	1.37	Mod	(R) mid-post	No	(R) G3, (L) G2	No	Day 4	PVL
13	27	0.95	Mod	(L) post	No	(R) G3, (L) G3	No	Day 2	PVL
14	27	1.09	Severe	(L) mid-post	No	(L) G3	No	Day 12	PVL
15	32	1.25	Mod	(R) post, (L) post	Yes	(R) G1	No	NA	PVL
16	30	<b>0.86</b>	Severe	(R) ant-mid-post, (L) ant-mid-post	Yes	None	No	Day 2	PVL
17	30	0.99	Mod	(R) mid-post	No	(L) G1	No	Day 2	PVL
18	28	1.19	Severe	(R) ant-mid-post, (L) ant-mid-post	Yes	None	No	Day 14	PVL
19	26	1.13	Mod	(R) mid-post, (L) mid-post	No	(R) G2, (L) G2	No	Day 2	PVL
20	25	1.02	Severe	(R) mid-post, (L) mid-post	Yes	(R) G3, (L) G3	No	Day 12	PVL
21	28	0.96	Mild	(R) post, (L) post	Yes	None	No	NA	PVL

GA, gestational age; ODA, optic disc area; IVH, intraventricular haemorrhage; PVH, periventricular haemorrhage; PVL, periventricular leucomalacia; NA, not able to accurately time the ischaemic insult.

\*Only patient with normal sized disc but a large optic cup.

†Ant, mid, and post refer to the frontal, parietal, and occipital regions of the periventricular white matter, respectively.

The ODA values in bold type indicate the small optic discs.

degeneration across the geniculate body.<sup>25</sup> Jacobson *et al* have postulated that “early” prenatal damage to the white matter, before the supporting tissues around the optic nerve are fully developed, results in smaller optic disc size.<sup>13</sup> The median time of injury for the four patients with the small discs in our IVH 4 (PVH) group was 26 weeks.

Jacobson *et al* also reported that abnormal disc morphology in a child with PVL or PVH could be used to time the brain insult; a small optic disc area was only seen in children with white matter damage estimated to have occurred before 28 gestational weeks and a large cup area in a normal sized disc occurred after 28 weeks of gestation.<sup>13</sup> While four of the five patients with small optic disc area and PVWM damage in our study had evidence of ischaemic brain insult before 28 weeks of gestation, one of the patients (patient 16 in table 5) was estimated to have sustained the injury at 30 weeks gestation. Only one patient with PVWM damage in our study (patient 5 in table 5) had a large cup in a normal sized disc. This patient had periventricular haemorrhage (IVH 4), estimated to have occurred at 28 weeks gestation, with no evidence of PVL on CUSS or on MRI at 2 years of age (fig 6). Jacobson *et al* hypothesised that the increased cupping reflected damage caused by a “later” lesion in the PVWM and that, as the scleral canal around the optic nerve had fully developed, the degeneration of neural tissue resulted in a loss of optic nerve substance rather than any overall change in optic disc size.<sup>13</sup> We were unable to demonstrate a statistically significant association between disc morphology and timing of insult. The methodology used by Jacobson *et al* in distinguishing between PVH and PVL and in attributing a time of insult to the PVWM damage has already been questioned by Brodsky.<sup>17</sup>

This is the first study to look at the optic nerve status in premature infants using the image analysis facility on the RetCam 120. The size of the optic disc on RetCam images is influenced by the anatomical dimensions of the eye and optical aberrations. In adults, correction of optic disc measurements on fundal photographs is possible using magnification correction formulas (Bengtsson and Krakau, Littman).<sup>26–27</sup> These corrections are based on the premise that refraction is strongly correlated to axial length. In premature babies, myopia is caused by a more curved cornea, a thicker lens and a shallower anterior chamber depth rather than an increase in axial length.<sup>28</sup> Therefore, these adult correction methods are not applicable to premature children.<sup>29</sup> Pach *et al* have shown that, unlike axial myopia, refractive myopia is not associated with magnification and therefore a correction factor is not necessary.<sup>30</sup> Rimmer *et al* have shown, in an autopsy study, that growth of the normal optic disc and nerve is only 50% complete at 20 weeks gestation and 75% complete by full term.<sup>31</sup> Our results for mean horizontal ODD at 33–34 weeks gestational age (1.03 (SD 0.12) mm) correlate well with their findings for autopsy eyes in babies of less than 40 weeks gestation, especially when allowance is made for tissue shrinkage (Sylvester and Ari reported an average of 12.3% shrinkage in the diameter of the optic nerve after formalin fixation)—Rimmer *et al* 0.93 (SD 0.15) mm and Rimmer *et al* modified for shrinkage 1.06 (SD 0.17) mm.<sup>32</sup>

Premature infants with IVH 4 represented 8.3% of our study population. Other authors have reported an incidence of 4–15% for IVH 4 in the preterm neonate.<sup>3–33</sup> As our study was based on the analysis of fundal images taken for ROP screening, it included only those infants less than 31 weeks gestational age and/or  $\leq 1500$  g birth weight. However, PVWM damage (IVH 4 and PVL) typically occurs between 24–34 weeks of gestation.<sup>12</sup> Our study population, therefore, cannot be regarded as representative of all premature babies at risk for IVH.

Using the image analysis software of the RetCam 120, we have objectively measured the optic discs of premature babies and have demonstrated that 44% of babies with IVH 4 had

ONH. As ONH may have significant neurological and visual implications we recommend that preterm infants with Grade 4 IVH be referred for ophthalmological evaluation even when they fall outside ROP screening criteria.

#### Authors' affiliations

**E McLoone, M O'Keefe, N Horgan, B Lanigan**, Department of Ophthalmology, Children's University Hospital, Temple Street, Dublin and University College Dublin, Republic of Ireland  
**V Donoghue**, Department of Radiology, Children's University Hospital, Temple Street, Dublin, Republic of Ireland  
**S McLoone**, Department of Electronic Engineering, NUI Maynooth, Maynooth, Co Kildare, Republic of Ireland

#### REFERENCES

- 1 Yin R, Reddihough DS, Ditchfield MR, *et al*. Magnetic resonance imaging findings in cerebral palsy. *J Pediatr Child Health* 2000;**36**:139–44.
- 2 Hutchison AA, Barrett JM, Fleischer AC. Intraventricular haemorrhage in the premature infant. *N Eng J Med* 1982;**307**:1272–3.
- 3 Volpe JJ. Intraventricular haemorrhage in the premature infant—current concepts. Part I. *Ann Neurol* 1989;**25**:3–11.
- 4 Brodsky MC, Glasier CM. Optic nerve hypoplasia: clinical significance of associated central nervous system abnormalities on magnetic resonance imaging. *Arch Ophthalmol* 1993;**111**:66–74.
- 5 Algawi K, Beigi B, Asady M, *et al*. Ophthalmological sequelae following post-haemorrhagic hydrocephalus. *Neuro-ophthalmology* 1995;**15**:97–101.
- 6 King KM, Cronin CM. Ocular findings in premature infants with grade 4 intraventricular haemorrhage. *J Pediatr Ophthalmol Strabismus* 1993;**30**:84–7.
- 7 Burke JP, O'Keefe M, Bowell R. Optic nerve hypoplasia, encephalopathy, and neurodevelopmental handicap. *Br J Ophthalmol* 1991;**75**:236–9.
- 8 Frisen L, Holmegaard L. Spectrum of optic nerve hypoplasia. *Br J Ophthalmol* 1978;**62**:7–15.
- 9 Jacobson L, Hellstrom A, Flodmark O. Large cups in normal-sized optic discs: a variant of optic nerve hypoplasia in children with periventricular leucomalacia. *Arch Ophthalmol* 1997;**115**:1263–9.
- 10 Hoyt CS, Good WV. Do we really understand the difference between optic nerve hypoplasia and atrophy? *Eye* 1992;**6**:201–4.
- 11 Hellstrom A. Optic nerve morphology may reveal adverse events during prenatal and perinatal life—digital image analysis. *Surv Ophthalmol* 1999;**44**(Suppl 1):63–73.
- 12 Hellstrom A, Hard AL, Svensson E, *et al*. Ocular fundus abnormalities in children born before 29 weeks of gestation: a population-based study. *Eye* 2000;**14**:324–9.
- 13 Jacobson L, Hard AL, Svensson E, *et al*. Optic disc morphology may reveal timing of insult in children with periventricular leucomalacia and/or periventricular haemorrhage. *Br J Ophthalmol* 2003;**87**:1345–9.
- 14 Papile LA, Burstein J, Burstein R, *et al*. Incidence and evolution of subependymal and intraventricular haemorrhage: a study of infants with birth weights less than 1500 g. *J Pediatrics* 1978;**92**:529–34.
- 15 Debillion T, N'Guyen S, Muet A, *et al*. Limitations of ultrasonography for diagnosing white matter damage in preterm infants. *Arch Dis Child Fetal Neonatal Ed* 2003;**88**:F275–9.
- 16 Flodmark O, Lupton B, Li D, *et al*. MR imaging of periventricular leucomalacia in childhood. *AJNR* 1989;**10**:111–18.
- 17 Brodsky MC. Semiology of periventricular leucomalacia and its optic disc morphology. *Br J Ophthalmol* 2003;**87**:1309–10.
- 18 Berger R, Bender S, Sefkow S, *et al*. Peri/intraventricular haemorrhage: a cranial ultrasound study on 5286 neonates. *Eur J Obstet Gynaecol Biol* 1997;**75**:191–203.
- 19 Van de Bor M, Verloove-Vanhorick SP, Brand R, *et al*. Incidence and prediction of periventricular-intraventricular haemorrhage in very preterm infants. *J Perinat Med* 1987;**15**:333–9.
- 20 Amato M, Pasquier S, von Muralt G, *et al*. Incidence of retinopathy of prematurity in low birth weight infants with peri-ventricular hemorrhage. *Neuropediatrics* 1986;**17**:191–2.
- 21 Phillips J, Christiansen SP, Ware G, *et al*. Ocular morbidity in very low birth weight infants with intraventricular haemorrhage. *Am J Ophthalmol* 1997;**123**:218–23.
- 22 O'Keefe M, Kafil-Hussain N, Flitcroft I, *et al*. Ocular significance of intraventricular haemorrhage in premature infants. *Br J Ophthalmol* 2001;**85**:357–9.
- 23 Hungerford J, Stewart A, Hope P. Ocular sequelae of preterm birth and their relation to ultrasound evidence of cerebral damage. *Br J Ophthalmol* 1986;**70**:463–8.
- 24 Christiansen SP, Fray KJ, Spencer T. Ocular outcomes in low birth weight premature infants with intraventricular haemorrhage. *J Pediatr Ophthalmol Strabismus* 2002;**39**:157–65.
- 25 Brodsky MC, Glasier CM. Optic nerve hypoplasia. Clinical significance of associated central nervous system abnormalities on magnetic resonance imaging. *Arch Ophthalmol* 1993;**111**:66–74.
- 26 Bengtsson B, Krakau CET. Correction of optic disc measurements on fundus photographs. *Graefes Arch Clin Exp Ophthalmol* 1992;**230**:24–8.
- 27 Littman H. Determination of the real size of an object on the fundus of the living eye. *Klin Monatsbl Augenheilkd* 1982;**180**:286–9.

- 28 **Gordon RA**, Donzis PA. Refractive development of the human eye. *Arch Ophthalmol* 1985;**103**:785-9.
- 29 **Hellstrom A**, Hard AL, Chen Y, *et al*. Ocular fundus morphology in preterm children. Influence of gestational age, birth size, perinatal morbidity and postnatal growth. *Invest Ophthalmol Vis Sci* 1997;**38**:184-92.
- 30 **Pach J**, Pennell DO, Romano PE. Optic disc photogrammetry: magnification factors for eye position, centration, and ametropias, refractive and axial; and their application in the diagnosis of optic nerve hypoplasia. *Ann Ophthalmol* 1989;**21**:454-62.
- 31 **Rimmer S**, Keating C, Chou T, *et al*. Growth of the human optic disc and nerve during gestation, childhood, and early adulthood. *Am J Ophthalmol* 1993;**116**:748-53.
- 32 **Sylvester PE**, Ari K. The size and growth of the human optic nerve. *J Neurol Neurosurg Psychiatry* 1961;**24**:45-7.
- 33 **Trounce JQ**, Rutter N, Levene ML. Periventricular leucomalacia and intraventricular haemorrhage in the preterm neonate. *Arch Dis Childhood* 1986;**61**:1196-202.

### Clinical Evidence—Call for contributors

*Clinical Evidence* is a regularly updated evidence-based journal available worldwide both as a paper version and on the internet. *Clinical Evidence* needs to recruit a number of new contributors. Contributors are healthcare professionals or epidemiologists with experience in evidence-based medicine and the ability to write in a concise and structured way.

#### Areas for which we are currently seeking contributors:

- Pregnancy and childbirth
- Endocrine disorders
- Palliative care
- Tropical diseases

We are also looking for contributors for existing topics. For full details on what these topics are please visit [www.clinicalevidence.com/ceweb/contribute/index.jsp](http://www.clinicalevidence.com/ceweb/contribute/index.jsp)

However, we are always looking for others, so do not let this list discourage you.

#### Being a contributor involves:

- Selecting from a validated, screened search (performed by in-house Information Specialists) epidemiologically sound studies for inclusion.
- Documenting your decisions about which studies to include on an inclusion and exclusion form, which we keep on file.
- Writing the text to a highly structured template (about 1500-3000 words), using evidence from the final studies chosen, within 8-10 weeks of receiving the literature search.
- Working with *Clinical Evidence* editors to ensure that the final text meets epidemiological and style standards.
- Updating the text every 12 months using any new, sound evidence that becomes available. The *Clinical Evidence* in-house team will conduct the searches for contributors; your task is simply to filter out high quality studies and incorporate them in the existing text.

If you would like to become a contributor for *Clinical Evidence* or require more information about what this involves please send your contact details and a copy of your CV, clearly stating the clinical area you are interested in, to [CECommissioning@bmjgroup.com](mailto:CECommissioning@bmjgroup.com).

### Call for peer reviewers

*Clinical Evidence* also needs to recruit a number of new peer reviewers specifically with an interest in the clinical areas stated above, and also others related to general practice. Peer reviewers are healthcare professionals or epidemiologists with experience in evidence-based medicine. As a peer reviewer you would be asked for your views on the clinical relevance, validity, and accessibility of specific topics within the journal, and their usefulness to the intended audience (international generalists and healthcare professionals, possibly with limited statistical knowledge). Topics are usually 1500-3000 words in length and we would ask you to review between 2-5 topics per year. The peer review process takes place throughout the year, and our turnaround time for each review is ideally 10-14 days.

If you are interested in becoming a peer reviewer for *Clinical Evidence*, please complete the peer review questionnaire at [www.clinicalevidence.com/ceweb/contribute/peerreviewer.jsp](http://www.clinicalevidence.com/ceweb/contribute/peerreviewer.jsp)